

Review: Clinical, genetic and neuroimaging features of frontotemporal dementia

R. Convery*, S. Mead† and J. D. Rohrer* 

*Dementia Research Centre, Department of Neurodegenerative Disease, UCL Queen Square Institute of Neurology and

†UCL Institute of Prion Diseases, MRC Prion Unit at UCL, London, UK

R. Convery, S. Mead, J. D Rohrer (2019) *Neuropathology and Applied Neurobiology* 45, 6–18

Clinical, genetic and neuroimaging features of frontotemporal dementia

Frontotemporal dementia (FTD) is a heterogeneous group of disorders causing neurodegeneration within a network of areas centred on the frontal and temporal lobes. Clinically, patients present with behavioural symptoms (behavioural variant FTD) or language disturbance (primary progressive aphasia), although there is an overlap with motor neurone disease and atypical parkinsonian disorders. Whilst neuroimaging commonly reveals abnormalities in the frontal and temporal lobes, a closer review identifies a more complex picture with variable asymmetry of neuronal loss, widespread subcortical

involvement and in many cases more posterior cortical atrophy. An autosomal-dominant genetic disorder is found in around a third of people with mutations in progranulin, *C9orf72* and the microtubule-associated protein tau being the commonest causes. In the other two-thirds, the disorder is sporadic, although recent genome-wide association studies have started to identify genetic risk factors within this group. Much of this knowledge has been understood only in the past 10 years and so this review will discuss the current knowledge about the clinical, genetic and neuroimaging features of FTD.

Keywords: frontotemporal dementia

Introduction

Frontotemporal dementia (FTD) is a term used to describe a clinically diverse group of disorders that are characterized by atrophy of the frontal and temporal lobes [1]. This selective pattern of degeneration results in the clinical phenotypes of behavioural and language variants of FTD [2–4]. Behavioural variant FTD (bvFTD) presents with a distinct change in behaviour and personality, whilst language variants, or primary progressive aphasias (PPA), are associated with progressive decline in speech and language functions. There are a number of subtypes of PPA including semantic variant (svPPA), nonfluent variant (nfvPPA)

and the logopenic variant (lvPPA), although this latter form is commonly not incorporated into the FTD clinical spectrum due to its common association with Alzheimer's disease (AD) pathology [5,6]. Overlap with other neurodegenerative conditions adds to the complexity of the FTD clinical spectrum: some patients with FTD can develop motor neurone disease (MND) or parkinsonian disorders such as corticobasal syndrome (CBS) and progressive supranuclear palsy (PSP).

FTD is not just clinically heterogeneous but is associated with diverse underlying pathology (inclusions of abnormal tau, TDP-43 or FUS protein), and in around a third of cases is caused by a genetic mutation, usually in the *MAPT*, *GRN* or *C9orf72* genes. Clinicopathological and clinico-genetic correlation is poor; bvFTD is associated with a range of underlying pathologies including tau, TDP-43 and FUS [7,8] and whilst svPPA is commonly associated with TDP-43

Correspondence: Dr Jonathan Rohrer, Dementia Research Centre, Department of Neurodegenerative Disease, UCL Queen Square Institute of Neurology, Queen Square, London, WC1N 3BG, UK. Tel: 0845 155 5000; E-mail: j.rohrer@ucl.ac.uk

inclusions and nfvPPA with tau pathology [9–11], there is no absolute association between one of the clinical FTD subtypes and a single pathological entity.

Clinical features

Behavioural variant FTD (Table 1)

BvFTD is the most common variant of FTD accounting for approximately 50% of all cases [12]. The condition is associated with atrophy of the frontal and anterior temporal lobes [13], accounting for the hallmark changes in behaviour and personality which include disinhibition, apathy, lack of empathy, obsessiveness and altered food preferences. Disinhibited behaviour may incorporate embarrassing social interactions, impulsivity, excessive spending or even gambling [14–16]. Apathy is usually described as “blunted affect”, or a decreased interest in engaging in social situations or activities that one previously found enjoyable [17]. Individuals with bvFTD that lack empathy are unable to read the emotions of others or understand their experiences [18]. Obsessive behaviours that arise can be simple repetitive movements such as tapping, scratching and rubbing, whilst more complex ritualistic behaviours include hoarding, cleaning rituals and fixed walking routines [19]. Finally, dietary changes can range from binge eating to idiosyncratic food preferences and are frequently associated with cravings for sweet foods [20]. These behavioural symptoms start insidiously and gradually progress over time.

Cognitively, bvFTD is most commonly associated with a decline in executive function. Individuals may struggle with tasks associated with planning, problem-solving, mental flexibility, attention and working memory [21]. Problems in these tasks reflect a decline in frontal cortical functions (and their connections), whereas other cognitive abilities attributed to more posterior regions of the brain, such as episodic memory and visuospatial abilities, are commonly initially well preserved. However, there have been a number of people with pathologically confirmed bvFTD who have been described with early semantic or even episodic memory impairment.

A lack of insight is a common feature in bvFTD, as patients fail to recognize the changes in their behaviour and personality [22]. Consequently, they rarely seek medical advice, and are often diagnosed due to a

relative or colleague suggesting an appointment. Patients can become agitated when their mental state is scrutinized, as they feel there is nothing wrong with them. A lack of insight is also associated with poor compliance with medication [23] and increased stress and caregiver burden [24].

BvFTD is difficult to diagnose for numerous reasons. Changes in behaviour can be subtle, and thus considered “normal”, whilst other symptoms overlap with psychiatric disorders or those seen in Alzheimer’s disease rather than FTD [25] and thus result in a misdiagnosis. Despite advances in the characterization of FTD, frequent misdiagnoses demanded sensitive diagnostic criteria that could distinguish bvFTD from other disorders early in the disease. This led to the development of the International FTD Consortium diagnostic criteria for bvFTD [3] (Table 1): patients must possess at least three of the six clinical features: five of which are behavioural (early behavioural disinhibition, apathy or inertia, loss of sympathy or empathy, stereotyped compulsive or ritualistic behaviour, and hyperorality and dietary changes) and one cognitive (executive deficits with relative sparing of episodic memory).

People with bvFTD can also present with other features that are not included in the Rascovsky *et al.*, (2011) criteria. In addition to altered behaviour, psychiatric symptoms can present in a minority of people with bvFTD. These include psychotic delusions, and multimodal hallucinations [26–28]. Such symptoms have even been observed as the earliest manifestations of disease in some individuals with *C9orf72* mutations [29]. Other psychiatric symptoms include late-onset mania, depression and cognitive impairment with catatonia [28]. Deficits in social cognition are observed in virtually all patients with bvFTD, and present as impaired emotion recognition [30–32], emotional morality [33] and theory of mind [34]. A lack of social emotions can be extremely difficult for close family members to manage, as embarrassing social situations can ensue. As a result, it is not uncommon for relationships to break down in bvFTD families, and thus social deficits in bvFTD are now recognized as important features of the disorder [35,36]. Several studies have shown that patients with bvFTD also experience autonomic problems, particularly with regards to altered responsiveness to pain and impaired thermoregulation [37]. Lastly, sleep disturbance can be a feature of FTD including excessive daytime sleepiness [38]. Therefore, the clinical

Table 1. Summary of symptoms within the current diagnostic criteria for bvFTD

<i>Behavioural/cognitive symptoms – diagnosis of possible bvFTD requires at least three of the following symptoms to be fulfilled:</i>	<i>Examples of specific symptoms</i>
Early behavioural disinhibition ≥ 1 of Socially inappropriate behaviour	Staring, inappropriate physical contact with strangers, inappropriate sexual behaviour, verbal or physical aggression
Loss of manners or decorum	Lack of social etiquette, insensitive or due comments, preference for crass jokes and slapstick humour, inappropriate choice of clothing or gifts
Impulsive, rash or careless actions	New gambling behaviour, driving or investing recklessly, overspending, gullibility to phishing/Internet scams
Early apathy or inertia ≥ 1 of Apathy	Reduced drive, stops previous hobbies, stops going out, reduced bathing or personal care
Inertia	Lack of persistence or completion of an activity, does not initiate activities or conversations
Early loss of sympathy or empathy ≥ 1 of Diminished response to other people's needs and feelings	Selfish or hurtful comments or actions, inability to perceive when someone is upset, embarrassed, or in pain, reduced appreciation of sarcasm or sophisticated humour
Diminished social interest, interrelatedness, or personal warmth	Emotionally cold or detached, lack of rapport in conversation, loss of interest or affection in relationships with friends or family members, reduced interest in sex
Early perseverative, stereotyped or Compulsive/ritualistic behaviour ≥ 1 of Simple repetitive movements	Repetitive rocking, tapping, clapping or rubbing
Complex, compulsive or ritualistic behaviours	Hoarding, strict grooming or walking routines, timekeeping and counting, checking or sorting items, cleaning or tidying, new obsessions or interests (usually spiritual, religious, artistic or musical)
Stereotypy of speech	Habitual repetition of particular words, sentences or topics
Hyperorality and dietary changes ≥ 1 of Altered food preferences	Sweet tooth (sweets, biscuits, ice cream), carbohydrates or obsessive food fads
Binge eating, increased consumption of alcohol or cigarettes	Cramming food into mouth, overeating or messy eating, new addictions to alcohol or smoking
Oral exploration or consumption of inedible objects	Pica
Neuropsychological profile – all three of Deficits in executive tasks	Vary as per neuropsychological assessment used
Relative sparing of episodic memory	
Relative sparing of visuospatial skills	

Table content adapted from Woollacott and Rohrer (2016) [118]. Criteria of possible bvFTD require that symptoms be persistent or recurrent, rather than single events. As a guideline, 'early' refers to within 3 years of initial symptom onset as per Rascovsky *et al.* (2011) [3]. bvFTD, behavioural variant frontotemporal dementia.

picture of bvFTD is one of diverse behavioural and cognitive deficits, with the combination of psychiatric, motor and autonomic disturbances often co-occurring.

It is important to note that there are some patients (commonly men in their 60's or 70's) who present with behavioural symptoms consistent with bvFTD but

without any cognitive deficits and lacking any changes on brain imaging. Whilst partners often complain of progressive symptoms over time, there are commonly few objective findings when assessed. These patients are often described as having a bvFTD 'phenocopy' syndrome [39] and whilst there are some very slowly

Table 2. Summary of clinical features of each PPA syndrome

Clinical features	svPPA	nfvPPA	lvPPA
Spontaneous speech (fluency, errors, grammar, prosody)	Fluent, garrulous and circumlocutory, grammatically correct and intact prosody	Decreased fluency, effortful (and/or) apraxic, phonetic errors, may be agrammatic	Hesitant, with slow output, long word-finding pauses, phonemic paraphasias, intact grammar and prosody
Single word comprehension	Impaired	Initially spared, but affected later on in disease	Initially spared, but affected later on in disease
Sentence comprehension	Initially preserved, becomes impaired later as word comprehension is impaired	Impaired for complex sentences	Impaired, especially if long
Single word repetition	Relatively intact	Mild to moderately impaired if polysyllabic, otherwise intact	Relatively intact (compared to sentence repetition)
Sentence repetition	Spared	Impaired if grammatically complex	Impaired with length effect
Naming	Severe anomia (nouns > verbs) with semantic paraphasias	Spared initially but anomic as disease progresses	Moderate anomia with occasional phonemic paraphasias
Reading	Surface dyslexia	Phonological dyslexia and possible phonetic errors when reading aloud	Phonological dyslexia
Writing	Surface dysgraphia	Phonological dysgraphia	Phonological dysgraphia

Clinical features adapted from table in Woollacott and Rohrer (2016) [118]. svPPA, semantic variant primary progressive aphasia; nfvPPA, nonfluent variant primary progressive aphasia; lvPPA, logopenic variant primary progressive aphasia.

progressive neurodegenerative variants of FTD, the majority of people fitting into this group do not have a degenerative illness. Exactly what they do have remains unclear as they are commonly alive many years after initial diagnosis and none have come to *post mortem*. However, it may represent a decompensation of a previous longstanding neuropsychiatric illness such as an autistic spectrum or personality disorder.

Primary progressive aphasia (Table 2)

The term PPA describes a group of disorders in which language impairment is the main symptom at onset [40]. There are three diagnostic criteria that should be fulfilled for all PPA disorders: (i) the insidious onset and gradual progression of aphasia affecting at least one of: speech production, object naming, syntax or word comprehension, (ii) language difficulties must be the only determinant that impacts upon activities of daily living and (iii) the disorder can only be explained by a neurodegenerative process and not by any other medical condition [4]. It is essential to meet all of these criteria for PPA as speech and language disorders can also arise due to

cerebrovascular conditions or other neurodegenerative disorders. Individuals with PPA can also present with behavioural deficits that are similar to bvFTD; however, these tend to develop later on in the disease and must not be the initial impairment. Once these criteria have been satisfied, patients can then be subdiagnosed into the three PPA variants: semantic variant (svPPA), nonfluent variant (nfvPPA) and logopenic variant (lvPPA). However, a subset of patients with PPA does not fulfil the criteria for any of these three variants, and have been classified as PPA – not otherwise specified, or PPA-NOS. For these patients, the clinical syndrome may become clearer throughout the disease course, where they can then be subdiagnosed, or it may not. Each PPA subtype presents with specific linguistic features and is associated with distinct neuroanatomical involvement [5]. The most recent classification system for the PPA syndromes was developed by Gorno-Tempini *et al.* (2011) and is shown in Table 2.

svPPA svPPA accounts for approximately 20% of all FTD cases [12]. The hallmark feature of this disorder is a profound loss of conceptual knowledge due to

dysfunction in the network crucial for semantic processing [41]. It is typically associated with bilateral, but usually asymmetrically worse on the left, atrophy of the anterior temporal lobes [42–44], with particular involvement of the inferior temporal gyri [45–47].

Patients with svPPA display a lack of semantic knowledge for objects, words and concepts which presents as impaired naming (or “anomia”) and word comprehension deficits [48]. SvPPA is also characterized by fluent spontaneous speech, which is garrulous, and difficult to interrupt. Frequent circumlocutory phrases (i.e. generally vague descriptions of a word), the use of empty words (e.g. thing) and semantic paraphasias (e.g. saying “fork” instead of “spoon”) are common features used to mask their lack of vocabulary [49,50]. Impaired object naming may start with low-frequency or less familiar words such as “labrador”. As the disease progresses, patients display more severe semantic difficulties and lose the grasp of broader concepts such as “dog”, and thus responses become increasingly general over time [51]. On neuropsychological testing, people with svPPA display anomia on confrontation naming tasks, impaired single word comprehension and difficulties with reading and writing that manifest as surface dyslexia and dysgraphia. For example, when reading aloud, patients pronounce irregularly spelt words phonetically (saying “sew” as “soo”) due to a lack of knowledge of the word. Progressive atrophy of the temporal and frontal lobes and the insular cortex also leads to the inability to associate meaning to other nonverbal stimuli including auditory [14,52], tactile [53] and olfactory [54] stimuli.

Behavioural change can also be a prominent feature of svPPA, as patients become obsessive over daily routines, develop eating problems and a range of behaviours similar to those seen in bvFTD [29,55,56].

svPPA was previously known as semantic dementia (SD), highlighting the loss of semantic knowledge as the key cognitive impairment in the disorder. This term was useful in that it allowed for patients to be included within this diagnostic label who presented with semantic loss in nonlanguage domains, or who had predominant semantic impairment but also had other features such as change in behaviour early on in the illness. For example, SD can also present with right (more than left) asymmetrical temporal lobe atrophy, a disorder often called either “right-sided SD” or just “right temporal lobe atrophy (RTLA)” [46,57–59]. The RTLA

variant is characterized by early behavioural changes rather than language impairment [59], and presents with other key distinguishing features such as an inability to recognize faces (prosopagnosia) [60,61]. RTLA patients also have more difficulties with topographical memory [59,62] and can develop other unusual features such as hyperreligiosity [63].

nfvPPA nfvPPA accounts for around 25% of FTD cases [12] and is characterized by impairment in speech production [4]. Symptoms arise due to atrophy of the left posterior and inferior frontal lobe, and insular cortex [44,64]. In contrast to the fluent speech observed in svPPA, individuals with nfvPPA display nonfluent “effortful” speech, with intact single word comprehension and object naming [65].

nfvPPA is characterized by agrammatism and/or impaired motor speech production, known as apraxia of speech. Speech agrammatism denotes the inappropriate ordering of words and the misuse of word endings, prepositions, pronouns, conjunctions and verb tenses. Patients with nfvPPA have difficulty constructing grammatically meaningful sentences, and use short, simple phrases that lack connecting words, resulting in “telegraphic” speech [66,67]. Comprehension deficits may start with sentences that are grammatically complex [68], before gradually progressing to complete incomprehension of conversational speech [66]. Some individuals with nfvPPA can develop binary word reversals, where they say the opposite word from what they intend to (e.g. “yes” instead of “no”) or respond to questions with “stock” phrases such as “I don’t know” in order to avoid spontaneous speech [69]. Over time speech can deteriorate to the point of mutism [5].

In some cases of nfvPPA, individuals display apraxia of speech, meaning they lack the ability to coordinate the motor aspects of speech production. Hesitancy and articulatory groping to find the correct speech sounds are common apraxic features [70]. Patients also display a slow rate of speech, off-target articulation, lengthened intersegment durations (between sounds, syllables, words or phrases), and sound distortions and substitutions that increase with increased utterance length and complexity [71]. Orofacial apraxia is often seen in association as well, and some patients will have accompanying limb apraxia [72].

nfvPPA can be considered a more heterogeneous disorder in comparison to other PPA subtypes: in some

patients agrammatism can be the most dominant feature, whilst others can display a presentation of isolated apraxia of speech. This has led some groups to distinguish further subtypes including agrammatic PPA and progressive apraxia of speech [73]. However, although distinct symptoms may be seen early on in the disease, as the disease progresses most patients tend to develop both apraxic and agrammatic features [72].

lvPPA lvPPA is characterized by long word-finding pauses which may result in nonfluent speech, false starts and constant re-wording of phrases [5,74]. This disorder can be distinguished from nfvPPA by the preservation of motor speech, that is, the lack of articulation deficits and the lack of frank agrammatism [4,6]. Impaired sentence (rather than single word) repetition adds to the clinical picture, and further dissociates this disorder from svPPA, although impaired object naming is seen in both conditions [5,74]. The hallmark neuroimaging feature of this disorder is asymmetrical (left greater than right) atrophy of the posterior superior temporal and inferior parietal lobes as well as posterior cingulate and medial temporal lobes [75]. Over time anomia and deficits in sentence repetition and sentence comprehension worsen, and ultimately single word comprehension and repetition become compromised [4]. The progression of symptoms reflects the increasing degeneration of the left hemisphere language network [76].

Although this disorder is part of the PPA spectrum, it is usually described as an atypical presentation of AD, rather than a subtype of FTD. Evidence from *post mortem* [6,9,77], PIB-PET imaging [11], and CSF tau and amyloid studies [6] has shown that lvPPA is commonly associated with AD, rather than FTD, pathology. As the disease develops impaired episodic memory, and posterior cortical cognitive deficits more typical of AD develop [78], further dissociating this condition from FTD.

Overlap syndromes

A number of associated motor disorders can overlap with FTD, including MND, PSP and CBS. In patients with overlap syndromes, motor symptoms can develop before, after or alongside the classic deficits of behaviour or language [79–81].

FTD-MND Overlap of FTD-MND occurs at genetic, pathological and clinical levels. The discovery of the

C9orf72 gene [82,83] and the identification of TDP-43 as the major protein inclusion in both FTD and MND [84] strengthened the association between these two conditions. Around 10–15% of patients with FTD develop MND, and symptoms can arise early or late in the disease course [85–87]. All FTD subtypes can occur with FTD-MND; however, it is most commonly seen in bvFTD, occasionally in nfvPPA, and rarely with svPPA. Similarly, around 15% of people with MND develop a clinical syndrome meeting the criteria for FTD; however, milder cognitive and behavioural abnormalities not meeting the criteria are also reported in 50–70% of patients [88,89]. Patients with FTD-MND have the shortest disease course of all forms of FTD, with an average of 2–3 years from symptom onset [90].

Parkinsonian disorders Progressive supranuclear palsy is a neurodegenerative disorder characterized by early postural instability resulting in backwards falls and impairment of vertical gaze [91]. This is the classical and most common phenotype of PSP, known as Richardson's syndrome, or PSP-RS [92,93]. However, recent diagnostic criteria have established a number of variant phenotypes of PSP including those with predominant parkinsonism (PSP-P), gait freezing (PSP-PGF) and ocular motor dysfunction (PSP-OM). The criteria also recognize the overlap with FTD, both bvFTD (called PSP-F in the criteria) and PPA, usually nfvPPA (called PSP-SL in the criteria) [94].

The clinical diagnostic criteria for CBS [the preferred clinical syndromic term for the disorder previously called corticobasal degeneration (CBD)] describe an asymmetric movement disorder combined with cortical deficits. The core features include: stiffness, clumsiness, asymmetric apraxia, rigidity, myoclonus, cortical sensory loss, visual/sensory hemineglect and alien limb phenomena [95–97]. As with PSP, overlap is commonly seen with both bvFTD [97] and nfvPPA [98].

Genetics

Frontotemporal dementia is a highly heritable disorder, with around a third of people having a family history of dementia or a movement disorder [99,100]. On closer inspection, this heritability is variable between the subtypes, with bvFTD the most commonly inherited (~40–45%) followed by FTD-MND, nfvPPA (~5%), CBS, PSP-RS and svPPA (<1%).

The majority of genetic FTD is accounted for by mutations in three genes: *C9orf72*, *GRN* and *MAPT*. The frequency of mutations is geographically variable, for example in the UK, there are approximately equal number of mutations seen in the three genes (~8–10% of all FTD), whilst in Italy, mutations in *GRN* are the most common. However, globally, *C9orf72* appears to be the most common genetic cause of FTD [101].

Mutations in all three genes are associated with a bvFTD phenotype. However, *GRN* can also be seen in people with PPA (often a syndrome not neatly fitting into one of the three clinical syndromes, PPA-NOS) and CBS. *C9orf72* can cause FTD-MND, or pure MND, and much less commonly a PPA syndrome or parkinsonian disorder. Patients with *C9orf72* mutations may have early neuropsychiatric symptoms including delusions and hallucinations. *MAPT* can cause a parkinsonian disorder (often CBS, and only very rarely PSP) and associated semantic impairment (although only extremely rarely a primary language disorder) [101].

Mutations in other genes are less common – the fourth most common cause of genetic FTD is mutations in the *TBKI* gene (~1% of all FTD) which can cause one (or a combination of) bvFTD, MND, PPA and CBS [102]. Mutations in *VCP* cause a very specific clinical syndrome of Inclusion Body Myopathy, Paget's disease and Frontotemporal Dementia (IBMPFD) with only a small number of families described across the world [103]. Mutations in *TARDBP*, *FUS* and *SQSTM1* have been described as causing an FTD syndrome but only in rare reports, and are more common causes of MND, whilst mutations in *CHMP2B* are the cause of a form of FTD seen in a large family in Denmark.

Next generation sequencing allows testing for mutations in multiple genes at the same time (although *C9orf72* expansions require testing for separately). Whilst this is a great advantage over previous individual testing, in that the referring physician no longer needs to have confidence in the clinical syndrome to make an accurate choice of gene, new approaches will lead to the more frequent identification of Variants of Uncertain Significance, variants with reduced penetrance and concurrent pathogenic mutations [104]. Closer collaboration between geneticists and clinicians is useful, but segregation and functional data may ultimately be necessary for an accurate classification of a

variant. In *GRN* mutations, a very low serum plasma or CSF progranulin (easily tested via ELISA) can be useful in determining pathogenicity [105].

Genome-wide association studies compare hundreds of thousands or millions of genetic polymorphisms between cases and controls. The approach has identified risk factors for sporadic forms of FTD and modifiers of the familial forms. The first such study analysed pathologically proven cases with TDP-43 pathology and identified multiple SNPs mapping to the *TMEM106B* gene [106]. Whilst replication of the finding in clinically diagnosed FTD was mixed, it is now clear that the minor allele of SNP rs1990622 is a strong protective factor (OR = 0.61) and also modifies the phenotype and penetrance of individuals with *GRN* mutations [106] or *C9orf72* [107–109]. Cell experiments that perturb *TMEM106B* suggest a link with lysosome function, but a direct connection with TDP-43 has not yet been established [109]. The largest genome-wide association study to date recruited clinical FTD cases, and identified the HLA locus as significant in the entire (mixed pathology) cohort and variants near to *RAB38/CTSC* in behavioural variant FTD [110], again implicating lysosomal function. Gene-based rather than SNP-based analysis of these data further identified an association of *APOE/TOMM40* with behavioural variant frontotemporal dementia, and *ARHGAP35* and *SERPINA1* with nvPPA, suggesting a role for *APOE* in pathologies other than Alzheimer's disease [111].

Neuroimaging (Figure 1)

The majority of neuroimaging studies of FTD have used magnetic resonance imaging (MRI), although a smaller number of studies have investigated positron emission tomography (PET) or single-photon emission computed tomography (SPECT) [112]. Diagnostically, the presence of frontotemporal atrophy, hypometabolism or hypoperfusion can be helpful, but behind this simplistic interpretation lies a more complex picture.

Firstly, early involvement of the insula and anterior cingulate makes FTD not just a frontal and temporal lobe disease [13]. This circuit is thought to be part of what has been termed a 'salience network', a set of functionally and structurally connected areas seen on neuroimaging but also linked at the cellular level by the presence of a specific set of cells called von Economo neurones [41]. Studies of presymptomatic FTD

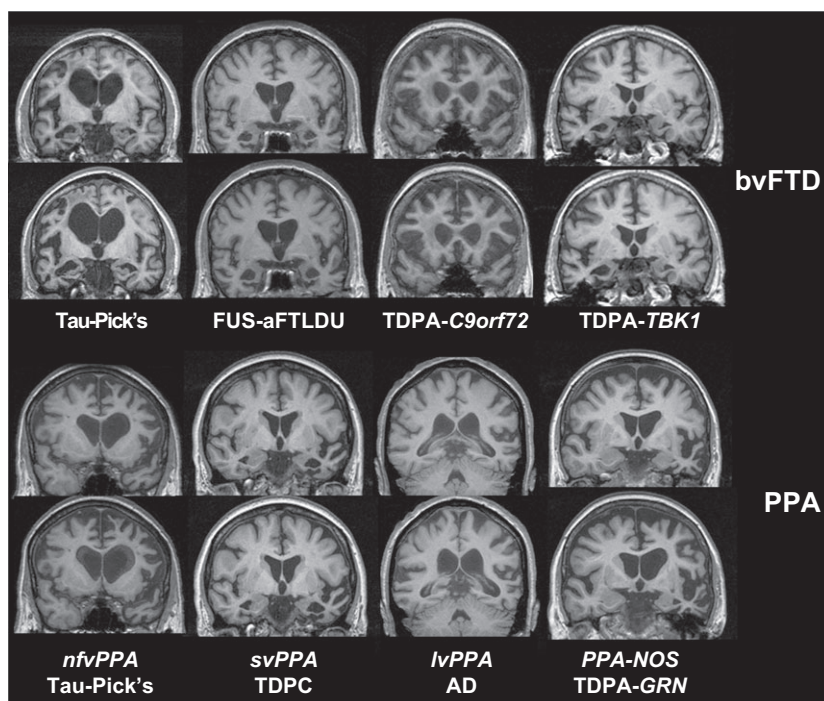


Figure 1. MR imaging features of different forms of frontotemporal dementia with both baseline coronal T1 scan and longitudinal scan at approximately 1 year interval. Top row shows different pathologically confirmed cases of bvFTD with features of (i) variable frontal, temporal, insula and anterior cingulate involvement, (ii) variable asymmetry and (iii) variable rate of progression. Bottom row shows characteristic features of different PPA variants in pathologically confirmed cases: left frontal and insula involvement in nvPPA, focal left more than right anteroinferior temporal involvement in svPPA, left temporo-parietal atrophy in lvPPA and very asymmetrical frontotemporal atrophy in PPA-NOS due to a progranulin mutation.

have suggested that the insula is the earliest area affected, around ten to fifteen years prior to symptom onset [101]. More posterior cortical involvement has been described even early in the disease in some forms of FTD, notably parietal lobe atrophy or hypometabolism in those with *GRN* mutations [112].

Secondly, there is early involvement of subcortical structures as well. Multiple studies have now shown atrophy of the hippocampus, amygdala, basal ganglia, thalamus, hypothalamus and habenula in FTD [10,13,43,113,114]. Involvement of the cerebellum is less common but is seen particularly in those with *C9orf72* mutations [115].

Thirdly, there is variable asymmetry in the pattern of neuroanatomical involvement [10]. Whilst some people with FTD have relatively symmetrical volume loss (particularly those with *C9orf72* and *MAPT* mutations), the majority of people (particularly those with PPA) have asymmetrical atrophy. In bvFTD, this is commonly right hemisphere predominant, but can also be left-sided predominant as well.

Lastly, rate of atrophy is variable between the different forms of FTD, for example in genetic FTD rates of brain atrophy are fastest (as a group) in those with *GRN* mutations (~3.5% whole brain atrophy per year) and slowest in *MAPT* mutations (~1.5%) [112]. Those with *C9orf72* mutations have more variable rates of atrophy with some progressing quickly and some very slowly [116]. This is important for future clinical trials, where such rates of atrophy may allow shorter trials in *GRN*-associated FTD [117].

Discussion

The diversity of clinical presentation within FTD, and the potential overlap of other conditions lead to considerable nosological and diagnostic difficulties. Modern-day sequencing has allowed wider access to genetic testing and whilst there are added complexities of interpreting novel variants, more people are being diagnosed with a form of genetic FTD than previously. Focusing on genetic FTD allows a molecular diagnosis

in life, and studies like the Genetic FTD Initiative, GENFI [101] are currently creating large cohorts of both symptomatic and presymptomatic mutation carriers ready for clinical trials. A more difficult problem is sporadic FTD where molecular diagnosis in life will require the development of novel biomarkers which may include PET or fluid markers (discussed elsewhere in this edition). There is still further research to be done in understanding the complex heterogeneous disease of frontotemporal dementia, but we are quickly approaching the era of therapeutic drug trials, and hopefully the first step towards a cure for this illness.

Author contributions

All authors contributed to the literature review and subsequent writing of this review.

References

- Graff-Radford N, Woodruff B. Frontotemporal dementia. *Semin Neurol* 2007; **27**: 48–57
- Hodges JR. Frontotemporal dementia (Pick's disease): clinical features and assessment. *Neurology* 2001; **56**: 6–10
- Rascovsky K, Hodges JR, Knopman D, Mendez MF, Kramer JH, Neuhaus J, et al. Sensitivity of revised diagnostic criteria for the behavioural variant of frontotemporal dementia. *Brain* 2011; **134**: 2456–77
- Gorno-Tempini M. Classification of primary progressive aphasia and its variants. *Neurology* 2011; **76**: 1006–14
- Gorno-tempini ML, Dronkers NF, Rankin KP, Ogar JM, Phengrasamy L, Rosen HJ, et al. Cognition and anatomy in three variants of primary progressive aphasia. *Ann Neurol* 2004; **55**: 335–46
- Rohrer JD, Rossor MN, Warren JD. Alzheimer's pathology in primary progressive aphasia. *Neurobiol Aging* 2012; **33**: 744–52
- Hodges JR, Davies RR, Xuereb JH, Casey B, Broe M, Bak TH, et al. Clinicopathological correlates in frontotemporal dementia. *Ann Neurol* 2004; **56**: 399–406
- Mackenzie IRA, Neumann M, Bigio EH, Cairns NJ, Alafuzoff I, Kril J, et al. Nomenclature and nosology for neuropathologic subtypes of frontotemporal lobar degeneration: an update. *Acta Neuropathol* 2009; **117**: 15–8
- Mesulam M, Wicklund A, Johnson N, Rogalski E, Léger GC, Rademaker A, et al. Alzheimer and frontotemporal pathology in subsets of primary progressive aphasia. *Ann Neurol* 2008; **63**: 709–19
- Rohrer JD, Lashley T, Schott JM, Warren JE, Mead S, Isaacs AM, et al. Clinical and neuroanatomical signatures of tissue pathology in frontotemporal lobar degeneration. *Brain* 2011; **134**: 2565–81
- Leyton CE, Villemagne VL, Savage S, Pike KE, Ballard KJ, Piguet O, et al. Subtypes of progressive aphasia: application of the international consensus criteria and validation using β -amyloid imaging. *Brain* 2011; **134**: 3030–43
- Johnson JK, Diehl J, Mendez MF, Neuhaus J, Shapira JS, Forman M, et al. Frontotemporal lobar degeneration. *Arch Neurol* 2005; **62**: 925–30
- Seeley WW, Crawford R, Rascovsky K, Kramer JH, Weiner M, Miller BL, et al. Frontal paralimbic network atrophy in very mild behavioral variant frontotemporal dementia. *Arch Neurol* 2008; **65**: 249–55
- Bozeat S, Gregory CA, Lambon Ralph MA, Hodges JR. Which neuropsychiatric and behavioural features distinguish frontal and temporal variants of frontotemporal dementia from Alzheimer's disease? *J Neurol Neurosurg Psychiatry* 2000; **69**: 178–86
- Starkstein SE, Garau ML, Cao A. Prevalence and clinical correlates of disinhibition in dementia. *Cogn Behav Neurol* 2004; **17**: 139–47
- Manes FF, Torralva T, Roca M, Gleichgerrcht E, Bekinschtein TA, Hodges JR. Frontotemporal dementia presenting as pathological gambling. *Nat Rev Neurol* 2010; **6**: 347–52
- Grossman M. Frontotemporal dementia: a review. *J Int Neuropsychol Soc* 2002; **8**: 566–83
- Rankin KP, Gorno-Tempini ML, Allison SC, Stanley CM, Glenn S, Weiner MW, et al. Structural anatomy of empathy in neurodegenerative disease. *Brain* 2006; **129**: 2945–56
- Snowden JS, Bathgate D, Varma A, Blackshaw A, Gibbons ZC, Neary D. Distinct behavioural profiles in frontotemporal dementia and semantic dementia. *J Neurol Neurosurg Psychiatry* 2001; **70**: 323–32
- Piguet O, Petersén Á, Yin Ka Lam B, Gabery S, Murphy K, Hodges JR, et al. Eating and hypothalamus changes in behavioral-variant frontotemporal dementia. *Ann Neurol* 2011; **69**: 312–9.
- Possin KL, Feigenbaum D, Rankin KP, Smith GE, Boxer AL, Wood K, et al. Dissociable executive functions in behavioral variant frontotemporal and Alzheimer dementias. *Neurology* 2013; **80**: 2180–5
- Rankin KP, Baldwin E, Pace-Savitsky C, Kramer JH, Miller BL. Self awareness and personality change in dementia. *J Neurol Neurosurg Psychiatry* 2005; **76**: 632–9
- McGlynn SM, Schacter DL. Unawareness of deficits in neuropsychological syndromes. *J Clin Exp Neuropsychol* 1989; **11**: 143–205
- O'Keefe FM, Murray B, Coen RF, Dockree PM, Bellgrove MA, Garavan H, et al. Loss of insight in frontotemporal dementia, corticobasal degeneration and progressive supranuclear palsy. *Brain* 2007; **130**: 753–64

- 25 Mendez MF, Shapira JS, McMurtray A, Licht E, Miller BL. Accuracy of the clinical evaluation for frontotemporal dementia. *Arch Neurol* 2007; **64**: 830–5
- 26 Takada LT, Sha SJ. Neuropsychiatric features of C9orf72-associated behavioral variant frontotemporal dementia and frontotemporal dementia with motor neuron disease. *Alzheimers Res Ther* 2012; **4**: 38
- 27 Kertesz A, Ang LC, Jesso S, MacKinley J, Baker M, Brown P, *et al.* Psychosis and hallucinations in frontotemporal dementia with the C9ORF72 mutation: a detailed clinical cohort. *Cogn Behav Neurol* 2013; **26**: 146–54
- 28 Ducharme S, Bajestan S, Dickerson BC, Voon V. Psychiatric presentations of C9orf72 mutation: what are the diagnostic implications for clinicians? *J Neuropsychiatry Clin Neurosci* 2017; **29**: 195–205
- 29 Snowden JS, Rollinson S, Thompson JC, Harris JM, Stopford CL, Richardson AMT, *et al.* Distinct clinical and pathological characteristics of frontotemporal dementia associated with C9ORF72 mutations. *Brain* 2012; **135**: 693–708
- 30 Rosen HJ, Pace-Savitsky K, Perry RJ, Kramer JH, Miller BL, Levenson RW. Recognition of emotion in the frontal and temporal variants of frontotemporal dementia. *Dement Geriatr Cogn Disord* 2004; **17**: 277–81.
- 31 Lough S, Gregory C, Hodges JR. Dissociation of social cognition and executive function in frontal variant frontotemporal dementia. *Neurocase* 2001; **7**: 123–30
- 32 Lough S, Kipps CM, Treise C, Watson P, Blair JR, Hodges JR. Social reasoning, emotion and empathy in frontotemporal dementia. *Neuropsychologia* 2006; **44**: 950–8
- 33 Mendez MF, Shapira JS. Altered emotional morality in frontotemporal dementia. *Cogn Neuropsychiatry* 2009; **14**: 165–79
- 34 Kumfor F, Piguet O. Disturbance of emotion processing in frontotemporal dementia: a synthesis of cognitive and neuroimaging findings. *Neuropsychol Rev* 2012; **22**: 280–97
- 35 LaMarre AK, Rascovsky K, Bostrom A, Toofanian P, Sarah Wilkins P, Sharon Sha BJ, *et al.* Interrater reliability of the new criteria for behavioral variant frontotemporal dementia. *Neurology* 2013; **80**: 1973–7
- 36 Harris JM, Gall C, Thompson JC, Richardson AM, David Neary C, du Plessis D, *et al.* Sensitivity and specificity of FTDC criteria for behavioral variant frontotemporal dementia. *Neurology* 2013; **80**: 1881–7
- 37 Fletcher PD, Downey LE, Golden HL, Clark CN, Slatery CF, Paterson RW, *et al.* Pain and temperature processing in dementia: a clinical and neuroanatomical analysis. *Brain* 2015; **138**: 3360–72
- 38 McCarter SJ, St. Louis EK, Boeve BF. Sleep disturbances in frontotemporal dementia. *Curr Neurol Neurosci Rep* 2016; **16**: 85.
- 39 Kipps CM, Hodges JR, Hornberger M. Nonprogressive behavioural frontotemporal dementia: recent developments and clinical implications of the “bvFTD phenotype syndrome”. *Curr Opin Neurol* 2010; **23**: 628–32
- 40 Mesulam M. Slowly progressive aphasia without generalized dementia. *Ann Neurol* 1982; **11**: 592–8
- 41 Seeley WW, Crawford RK, Zhou J, Miller BL, Greicius MD. Neurodegenerative diseases target large-scale human brain networks. *Neuron* 2009; **62**: 42–52
- 42 Hodges JR, Patterson K, Oxbury S, Funnell E. Semantic dementia: progressive fluent aphasia with temporal atrophy. *Brain* 1992; **115**: 1783–806
- 43 Whitwell JL, Josephs KA, Rossor MN, Stevens JM, Revesz T, Holton JL, *et al.* Magnetic resonance imaging signatures of tissue pathology in frontotemporal dementia. *Arch Neurol* 2005; **62**: 1402–8
- 44 Rohrer JD, Warren MJD, Modat FM, Ridgway GR, Douiri MA, Rossor MN, *et al.* Patterns of cortical thinning in the language variants of frontotemporal lobar degeneration. *Neurology* 2009; **72**: 1562–9
- 45 Mummery CJ, Patterson K, Price CJ, Ashburner J, Frackowiak RSJ, Hodges JR. A voxel-based morphometry study of semantic dementia: relationship between temporal lobe atrophy and semantic memory. *Ann Neurol* 2000; **47**: 36–45
- 46 Chan D, Fox NC, Scahill RI, Crum WR, Whitwell JL, Leschziner G, *et al.* Patterns of temporal lobe atrophy in semantic dementia and Alzheimer’s disease. *Ann Neurol* 2001; **49**: 433–42
- 47 Rohrer JD, McNaught E, Foster J, Clegg SL, Barnes J, Omar R, *et al.* Tracking progression in frontotemporal lobar degeneration: serial MRI in semantic dementia. *Neurology* 2008; **71**: 1445–51
- 48 Warrington EK. The selective impairment of semantic memory. *Q J Exp Psychol* 1975; **27**: 635–57
- 49 Hodges JR, Patterson K. Semantic dementia: a unique clinicopathological syndrome. *Lancet Neurol* 2007; **6**: 1004–14
- 50 Fletcher PD, Warren JD. Semantic dementia: a specific network-opathy. *J Mol Neurosci* 2011; **45**: 629–36
- 51 Hoffman P, Meteyard L, Patterson K. Broadly speaking: vocabulary in semantic dementia shifts towards general, semantically diverse words. *Cortex* 2014; **55**: 30–42
- 52 Goll JC, Crutch SJ, Warren JD. Central auditory disorders: toward a neuropsychology of auditory objects. *Curr Opin Neurol* 2010; **23**: 617–27
- 53 Coccia M, Bartolini M, Luzzi S, Provinciali L, Lambon Ralph MA. Semantic memory is an amodal, dynamic system: evidence from the interaction of naming and object use in semantic dementia. *Cogn Neuropsychol* 2004; **21**: 513–27
- 54 Rami L, Loy CT, Hailstone J, Warren JD. Odour identification in frontotemporal lobar degeneration. *J Neurol* 2007; **254**: 431–5

- 55 Rosen HJ, Allison SC, Ogar JM, Amici S, Rose K, Dronkers N, *et al.* Behavioral features in semantic dementia vs other forms of progressive aphasia. *Neurology* 2006; **67**: 1752–6
- 56 Harris JM, Jones M, Gall C, Richardson AMT, Neary D, du Plessis D, *et al.* Co-occurrence of language and behavioural change in frontotemporal lobar degeneration. *Dement Geriatr Cogn Dis Extra* 2016; **6**: 205–13
- 57 Evans JJ, Heggs AJ, Antoun N, Hodges JR. Progressive prosopagnosia associated with selective right temporal lobe atrophy. *Brain* 1995; **118**: 1–13
- 58 Thompson SA, Patterson K, Hodges JR. Left/right asymmetry of atrophy in semantic dementia: behavioural-cognitive implications. *Neurology* 2003; **61**: 1196–203
- 59 Chan D, Anderson V, Pijnenburg Y, Whitwell J, Barnes J, Scahill R, *et al.* The clinical profile of right temporal lobe atrophy. *Brain* 2009; **132**: 1287–98
- 60 Hutchings R, Palermo R, Piguet O, Kumfor F. Disrupted face processing in frontotemporal dementia: a review of the clinical and neuroanatomical evidence. *Neuropsychol Rev* 2017; **27**: 18–30
- 61 Joubert S, Felician O, Barbeau E, Ranjeva J-P, Christophe M, Didic M, *et al.* The right temporal lobe variant of frontotemporal dementia. *J Neurol* 2006; **253**: 1447–58
- 62 González-Caballero G, Abellán-Miralles I, Sáenz-Sanjuan MJ. Right temporal lobe variant of frontotemporal dementia. *J Clin Neurosci* 2015; **22**: 1139–43
- 63 Edwards-Lee T, Miller BL, Benson DF, Cummings JL, Russell GL, Boone K, *et al.* The temporal variant of frontotemporal dementia. *Brain* 1997; **120**: 1027–40
- 64 Wilson SM, Dronkers NF, Ogar JM, Jang J, Growdon ME, Agosta F, *et al.* Neural correlates of syntactic processing in the nonfluent variant of primary progressive aphasia. *J Neurosci* 2010; **30**: 16845–54
- 65 Hodges JR, Patterson K. Nonfluent progressive aphasia and semantic dementia: a comparative neuropsychological study. *J Int Neuropsychol Soc* 1996; **2**: 511–24
- 66 Mesulam M-M. Primary progressive aphasia — a language-based dementia. *N Engl J Med* 2003; **349**: 1535–42
- 67 Rohrer JD, Knight WD, Warren JE, Fox NC, Rossor MN, Warren JD. Word-finding difficulty: a clinical analysis of the progressive aphasia. *Brain* 2007; **131**: 8–38
- 68 Grossman M, Moore P. A longitudinal study of sentence comprehension difficulty in primary progressive aphasia. *J Neurol Neurosurg Psychiatry* 2005; **76**: 644–9
- 69 Warren JD, Hardy CJ, Fletcher PD, Marshall CR, Clark CN, Rohrer JD, *et al.* Binary reversals in primary progressive aphasia. *Cortex* 2016; **82**: 287–9
- 70 Josephs KA, Duffy JR, Strand EA, Whitwell JL, Layton KF, Parisi JE, *et al.* Clinicopathological and imaging correlates of progressive aphasia and apraxia of speech. *Brain* 2006; **129**: 1385–98
- 71 Strand EA, Duffy JR, Clark HM, Josephs K. The apraxia of speech rating scale: a tool for diagnosis and description of apraxia of speech. *J Commun Disord* 2014; **51**: 43–50
- 72 Rohrer JD, Rossor MN, Warren JD. Apraxia in progressive nonfluent aphasia. *J Neurol* 2010; **257**: 569–74
- 73 Josephs KA, Duffy JR, Strand EA, Machulda MM, Sengem ML, Lowe VJ, *et al.* Syndromes dominated by apraxia of speech show distinct characteristics from agrammatic PPA. *Neurology* 2013; **81**: 337–45
- 74 Gorno-Tempini ML, Brambati SM, Ginex V, Ogar J, Dronkers NF, Marcone A, *et al.* The logopenic/phonological variant of primary progressive aphasia. *Neurology* 2008; **71**: 1227–34
- 75 Rohrer JD, Ridgway GR, Crutch SJ, Hailstone J, Goll JC, Clarkson MJ, *et al.* Progressive logopenic/phonological aphasia: erosion of the language network. *NeuroImage* 2010; **49**: 984–93
- 76 Rohrer JD, Caso F, Mahoney C, Henry M, Rosen HJ, Rabinovici G, *et al.* Patterns of longitudinal brain atrophy in the logopenic variant of primary progressive aphasia. *Brain Lang* 2013; **127**: 121–6
- 77 Spinelli EG, Mandelli ML, Miller ZA, Santos-Santos MA, Wilson SM, Agosta F, *et al.* Typical and atypical pathology in primary progressive aphasia variants. *Ann Neurol* 2017; **81**: 430–43
- 78 Ahmed S, De Jager CA, Haigh AMF, Garrard P. Logopenic aphasia in Alzheimer's disease: clinical variant or clinical feature? *J Neurol Neurosurg Psychiatry* 2012; **83**: 1056–62
- 79 Kertesz A, McMonagle P. The overlapping syndromes of the pick complex. *Curr Alzheimer Res* 2011; **8**: 224–8
- 80 Park HK, Chung SJ. New perspective on parkinsonism in frontotemporal lobar degeneration. *J Mov Disord* 2013; **6**: 1–8
- 81 Devenney E, Vucic S, Hodges JR, Kiernan MC. Motor neuron disease-frontotemporal dementia: a clinical continuum. *Expert Rev Neurother* 2015; **15**: 509–22
- 82 DeJesus-Hernandez M, Mackenzie IR, Boeve BF, Boxer AL, Baker M, Rutherford NJ, *et al.* Expanded GGGGCC hexanucleotide repeat in noncoding region of C9ORF72 causes chromosome 9p-linked FTD and ALS. *Neuron* 2011; **72**: 245–56
- 83 Renton AE, Majounie E, Waite A, Simón-Sánchez J, Rollinson S, Gibbs JR, *et al.* A hexanucleotide repeat expansion in C9ORF72 is the cause of chromosome 9p21-linked ALS-FTD. *Neuron* 2011; **72**: 257–68
- 84 Neumann M, Sampathu DM, Kwong LK, Truax AC, Micsenyi MC, Chou TT, *et al.* Ubiquitinated TDP-43

- in frontotemporal lobar degeneration and amyotrophic lateral sclerosis. *Science* 2006; **314**: 130–3
- 85 Lomen-Hoerth C, Anderson T, Miller B. The overlap of amyotrophic lateral sclerosis and frontotemporal dementia. *Neurology* 2002; **59**: 1077–9
- 86 Seelaar H, Jurgen Schelhaas H, Azmani A, Kusters B, Rosso S, Majoor-Krakauer D, *et al.* TDP-43 pathology in familial frontotemporal dementia and motor neuron disease without Progranulin mutations. *Brain* 2007; **130**: 1375–85
- 87 Burrell JR, Kiernan MC, Vucic S, Hodges JR. Motor neuron dysfunction in frontotemporal dementia. *Brain* 2011; **134**: 2582–94
- 88 Lillo P, Savage S, Mioshi E, Kiernan MC, Hodges JR. Amyotrophic lateral sclerosis and frontotemporal dementia: a behavioural and cognitive continuum. *Amyotroph Lateral Scler* 2012; **13**: 102–9
- 89 Byrne S, Elamin M, Bede P, Shatunov A, Walsh C, Corr B, *et al.* Cognitive and clinical characteristics of patients with amyotrophic lateral sclerosis carrying a C9orf72 repeat expansion: a population-based cohort study. *Lancet Neurol* 2012; **11**: 232–40
- 90 Elamin M, Phukan J, Bede P, Jordan N, Byrne S, Pender N, *et al.* Executive dysfunction is a negative prognostic indicator in patients with ALS without dementia. *Neurology* 2011; **76**: 1263–9
- 91 Litvan I, Agid Y, Calne D, Campbell G, Dubois B, Duvoisin RC, *et al.* Clinical research criteria for the diagnosis of progressive supranuclear palsy (Steele-Richardson-Olszewski syndrome). *Neurology* 1996; **47**: 1–9
- 92 Steele JC, Richardson JC, Olszewski J. Progressive supranuclear palsy. *Arch Neurol* 1964; **10**: 333–59
- 93 Williams DR, de Silva R, Paviour DC, Pittman A, Watt HC, Kilford L, *et al.* Characteristics of two distinct clinical phenotypes in pathologically proven progressive supranuclear palsy: Richardson's syndrome and PSP-parkinsonism. *Brain* 2005; **128**: 1247–58
- 94 Höglinger GU, Respondek G, Stamelou M, Kurz C, Josephs KA, Lang AE, *et al.* Clinical diagnosis of progressive supranuclear palsy: the movement disorder society criteria. *Mov Disord* 2017; **32**: 853–64
- 95 Riley DE, Lang AE, Lewis A, Resch L, Ashby P, Hornykiewicz O, *et al.* Cortical-basal ganglionic degeneration. *Neurology* 1990; **40**: 1203–12
- 96 Litvan I, Cummings JL, Mega M. Neuropsychiatric features of corticobasal degeneration. *J Neurol Neurosurg Psychiatry* 1998; **65**: 717–21
- 97 Bak TH, Hodges JR. Corticobasal degeneration: clinical aspects. *Handb Clin Neurol* 2008; **89**: 509–21
- 98 Graham NL, Bak TH, Hodges JR. Corticobasal degeneration as a cognitive disorder. *Mov Disord* 2003; **18**: 1224–32
- 99 Goldman JS, Farmer JM, Wood EM, Johnson JK, Boxer A, Neuhaus J, *et al.* Comparison of family histories in FTLD subtypes and related tauopathies. *Neurology* 2005; **65**: 1817–9
- 100 Rohrer JD, Guerreiro R, Vandrovцова J, Uphill J, Reiman D, Beck J, *et al.* The heritability and genetics of frontotemporal lobar degeneration. *Neurology* 2009; **73**: 1451–6
- 101 Rohrer JD, Nicholas JM, Cash DM, van Swieten J, Dopper E, Jiskoot L, *et al.* Presymptomatic cognitive and neuroanatomical changes in genetic frontotemporal dementia in the Genetic Frontotemporal dementia Initiative (GENFI) study: a cross-sectional analysis. *Lancet Neurol* 2015; **14**: 253–62
- 102 van der Zee J, Gijssels I, Van Mossevelde S, Perrone F, Dillen L, Heeman B, *et al.* *TBKI* mutation spectrum in an extended european patient cohort with frontotemporal dementia and amyotrophic lateral sclerosis. *Hum Mutat* 2017; **38**: 297–309
- 103 Nalbandian A, Donkervoort S, Dec E, Badadani M, Katheria V, Rana P, *et al.* The multiple faces of valosin-containing protein-associated diseases: inclusion body myopathy with paget's disease of bone, frontotemporal dementia, and amyotrophic lateral sclerosis. *J Mol Neurosci* 2011; **45**: 522–31
- 104 Koriath C, Kenny J, Adamson G, Druey R, Taylor W, Beck J, *et al.* Predictors for a dementia gene mutation based on gene-panel next-generation sequencing of a large dementia referral series. *Mol Psychiatry* (2018, in press).
- 105 Ghidoni R, Benussi L, Glionna M, Franzoni M, Binetti G. Low plasma progranulin levels predict progranulin mutations in frontotemporal lobar degeneration. *Neurology* 2008; **71**: 1235–9
- 106 Van Deerlin VM, Sleiman PMA, Martinez-Lage M, Chen-Plotkin A, Wang L-S, Graff-Radford NR, *et al.* Common variants at 7p21 are associated with frontotemporal lobar degeneration with TDP-43 inclusions. *Nat Genet* 2010; **42**: 234–9
- 107 Gallagher MD, Suh E, Grossman M, Elman L, McCluskey L, Van Swieten JC, *et al.* TMEM106B is a genetic modifier of frontotemporal lobar degeneration with C9orf72 hexanucleotide repeat expansions. *Acta Neuropathol* 2014; **127**: 407–18
- 108 van Blitterswijk M, Mullen B, Nicholson AM, Bieniek KF, Heckman MG, Baker MC, *et al.* TMEM106B protects C9ORF72 expansion carriers against frontotemporal dementia. *Acta Neuropathol* 2014; **127**: 397–406
- 109 Nicholson AM, Rademakers R. What we know about TMEM106B in neurodegeneration. *Acta Neuropathol* 2016; **132**: 639–51
- 110 Ferrari R, Hernandez DG, Nalls MA, Rohrer JD, Ramasamy A, Kwok JBJ, *et al.* Frontotemporal dementia and its subtypes: a genome-wide association study. *Lancet Neurol* 2014; **13**: 686–99
- 111 Mishra A, Ferrari R, Heutink P, Hardy J, Pijnenburg Y, Posthuma D. Gene-based association studies report genetic links for clinical subtypes of frontotemporal dementia. *Brain* 2017; **140**: 1437–46

- 112 Gordon E, Rohrer JD, Fox NC. Advances in neuroimaging in frontotemporal dementia. *J Neurochem* 2016; **138**: 193–210
- 113 Bocchetta M, Gordon E, Manning E, Barnes J, Cash DM, Espak M, et al. Detailed volumetric analysis of the hypothalamus in behavioral variant frontotemporal dementia. *J Neurol* 2015; **262**: 2635–42
- 114 Bocchetta M, Gordon E, Marshall CR, Slattery CF, Cardoso MJ, Cash DM, et al. The habenula: an under-recognised area of importance in frontotemporal dementia? *J Neurol Neurosurg Psychiatry* 2016; **87**: 910–2
- 115 Bocchetta M, Cardoso MJ, Cash DM, Ourselin S, Warren JD, Rohrer JD. Patterns of regional cerebellar atrophy in genetic frontotemporal dementia. *Neuroimage Clin* 2016; **11**: 287–90
- 116 Llamas-Velasco S, García-Redondo A, Herrero-San Martín A, Puertas Martín V, González-Sánchez M, Pérez-Martínez DA, et al. Slowly progressive behavioral frontotemporal dementia with C9orf72 mutation. Case report and review of the literature. *Neurocase* 2018; **24**: 68–71.
- 117 Sha SJ, Miller ZA, Min S, Zhou Y, Brown J, Mitic LL, et al. An 8-week, open-label, dose-finding study of nimodipine for the treatment of progranulin insufficiency from GRN gene mutations. *Alzheimers Dement* 2017; **3**: 507–12
- 118 Woollacott IOC, Rohrer JD. The clinical spectrum of sporadic and familial forms of frontotemporal dementia. *J Neurochem* 2016; **138**: 6–31

Received 27 September 2018

Accepted after revision 10 December 2018

Published online Article Accepted on 24 December 2018